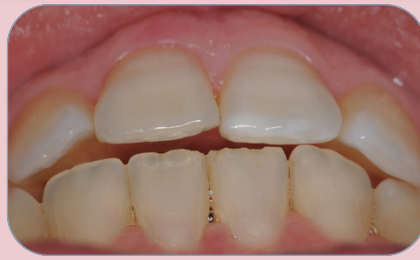

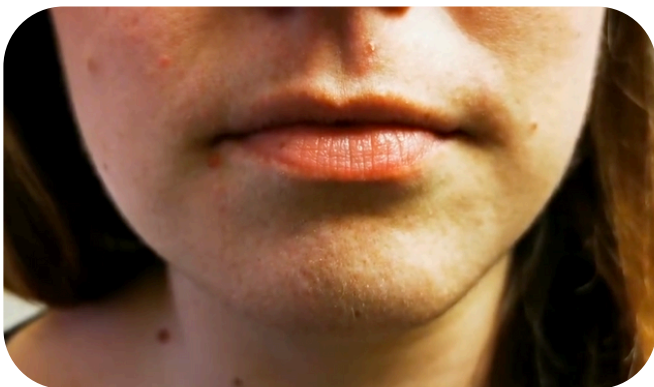**RELAPSE AFTER ORTHODONTIC
AND
SPEECH THERAPY TREATMENT**

Dr. Mauro Libertucci




THE ADOLESCENT PATIENT PRESENTS TO THE CLINIC AS SHE EXHIBITS A RELAPSE FOLLOWING A LENGTHY ORTHODONTIC AND SPEECH THERAPY TREATMENT.

SHE DISPLAYS TONGUE THRUST AND EVIDENT ATYPICAL SWALLOWING, AS HIGHLIGHTED BY THE TWO STILL FRAMES BELOW, EXTRACTED FROM THE VIDEO RECORDED IN THE CLINIC TO DOCUMENT THE CASE.

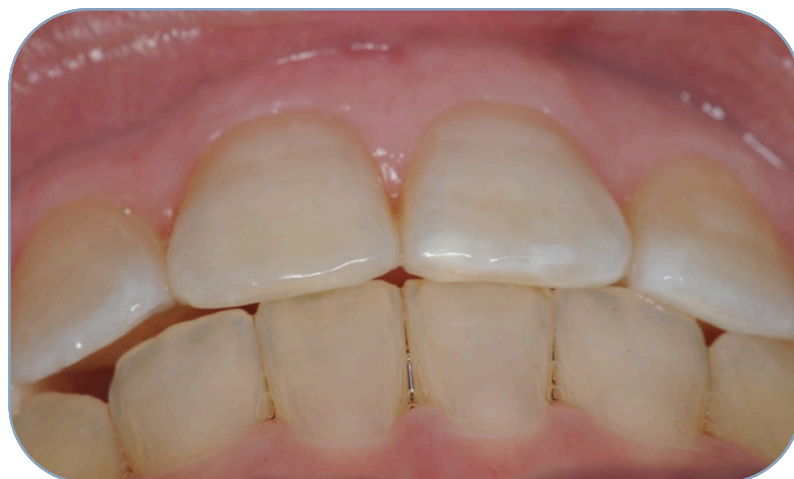

AT REST



SWALLOWING

AFTER JUST ONE MONTH OF TREATMENT WITH FROGGYMOUTH, A NATURAL REVERSAL OF THE RELAPSE IS OBSERVED DUE TO THE ELIMINATION OF THE CAUSES: TONGUE THRUST AND SUCTION-SWALLOWING.



IT WILL STILL BE NECESSARY TO COMPLETE THE TREATMENT ACCORDING TO THE PRESCRIBED PROTOCOL TO ENSURE THE STABILIZATION OF THE NEW SWALLOWING PATTERN.



FROGGYMOUTH